

## Clinical Perspective

# Lingual Frenulum Protocol

Irene Queiroz Marchesan (CEFAC, Sao Paulo)

### Suggested Citation

Marchesan, I. Q. (2012). Lingual Frenulum Protocol. *International Journal of Orofacial Myology*, 38(1), 89-103.

DOI: <https://doi.org/10.52010/ijom.2012.38.1.7>



This work is licensed under a [Creative Commons Attribution-NonCommercial-NoDerivatives 4.0 International License](https://creativecommons.org/licenses/by-nc-nd/4.0/).

The views expressed in this article are those of the authors and do not necessarily reflect the policies or positions of the International Association of Orofacial Myology (IAOM). Identification of specific products, programs, or equipment does not constitute or imply endorsement by the authors or the IAOM. The journal in which this article appears is hosted on [Digital Commons](https://digitalcommons.elsevier.com/), an Elsevier platform.

# LINGUAL FRENULUM PROTOCOL

IRENE QUEIROZ MARCHESAN, PHD

## ABSTRACT

An efficient lingual frenulum protocol with scores is presented. From a specific lingual frenulum evaluation used until 2004, a new protocol was designed. Ten speech language pathologists experienced in orofacial myology used the new protocol with different groups of subjects. 1235 subjects were evaluated during 3 years. From the experience of these ten speech language pathologists, the protocol was re-structured, and a scoring system was added. Absence of alteration (normal tongue and frenulum) was scored zero. The alterations observed were scored in ascending order. Four additional speech language pathologists experienced in orofacial myology were trained by the researcher to administer the final version of the protocol. The protocol was administered in 2008 and 2009 to 239 subjects: 160 children between 7 years and 2 months old and 11 years and 7 months old; and to 79 adults from 16 years and 8 months or older. **From the results of administration of the protocol, a new lingual frenulum protocol with scores was designed.** According to the scores, the frenulum can be considered altered or normal. When the sum of general tests is equal or higher than 3, the frenulum may be altered. The interference of the lingual frenulum in the oral functions may be considered when the sum of the functional tests is equal or higher than 25. This new lingual frenulum protocol with scores was designed and has been an efficient tool to diagnose an altered lingual frenulum.

**KEYWORDS:** Lingual frenulum, evaluation, tongue, speech articulation tests, speech, language and hearing sciences, classification

## INTRODUCTION

When health professionals evaluate the lingual frenulum, they diagnose it as normal or altered depending on the criteria used. Usually, professionals evaluate the lingual frenulum by observing the appearance and the mobility of the tongue. When assessing babies, health professionals also observe breastfeeding. For an accurate evaluation, it is necessary to observe certain aspects of the tongue and frenulum, such as the mobility and habitual position of the tongue, as well as speech articulation. In general, existing protocols only evaluate the mobility of the tongue and frenulum by itself, and the results depend on what the evaluator considers normal or altered.

The lingual frenulum definitions found in the literature complement each other, without indicating divergent key aspects (Kenneth, 1998; Singh & Kent, 2000; Zemlin, 2000; Moore & Dalley, 2001; Galvão, 2001; Stedman, 2003). There is a wide variation of nomenclature to define the altered frenulum: tongue-tie, short

frenulum, long frenulum, sticky tongue, anteriorized, ankyloglossia (full or partial), among others (Singh & Kent, 2000; Zemlin,

2000; Moore & Dalley, 2001; Galvão, 2001; Stedman, 2003; Dorland, 2004; Marchesan, 2004). As the terminology varies, contradictory diagnoses may occur (Segal, Stephenson, Dawes, Feldman, 2007; Suter & Bornstein, 2009). Although there is no consensus about terminology, all professionals agree that, when the lingual frenulum is altered, feeding and speech are frequently altered functions. In the literature breastfeeding is the most often cited altered function; however, breastfeeding lasts approximately only one year, while chewing, swallowing and speech are life-long functions (Messner Lalakea, Macmahon, Bair, 2000b; Ballard, Auer, Khoury, 2002; Hogan, Westcott, Griffiths, 2005; Hall & Renfrew, 2006; Geddes, Langton, Gollow, Jacobs, Hartmann, Simmer, 2008; Karabulut, Sonmez, Turkyilmaz, Demirogullari, Ozen, Bagbanci, 2008; Miranda & Milroy, 2010; Post, Rupert, Schulpen, 2010; Forlenza, Black, McNamara, Sullivan, 2010; Merdad & Mascarenhas, 2010).

When the lingual frenulum is altered the greatest divergence from normal is in the area of speech production. Some studies claim that such alterations are rare or insignificant (Zemlin, 2000; Moore & Dalley, 2001). In addition, other authors claim that the incidence of speech disorders is low (Navarro & Lópes, 2002;

Gonçalves & Ferreiro, 2006; Karabulut et al, 2008), while others say that it is difficult to relate altered frenulum to speech alterations (Suter & Bornstein, 2009; Merdad & Mascarenhas, 2010). In addition, other authors suggest that the occurrence of speech distortions in subjects with altered frenulum is present in 50% of the cases (Lalakea & Messner, 2003; Marchesan, 2004; Marchesan et al, 2009). Perhaps the authors who do not relate altered speech to altered frenulum are the ones who consider only omissions and substitutions as speech alterations, without considering distortions, which are the most frequent alterations.

The divergence of views is not only regarding terminologies, but also the consequences of the altered frenulum. Frenulum surgeries are also the subjects of divergence, since there are frequent questions about whether to perform surgery or not, when to perform surgery, what the best technique is for the surgery, and, even, who would be the most qualified professional to perform it (Messner & Lalakea, 2000; Navarro & Lopes, 2002; Hogan et al, 2005; Wallace & Clarke, 2006; Geddes et al, 2008; Suter & Bornstein, 2009; Miranda & Milroy, 2010; Knox, 2010; Tuli & Singh, 2010). This diversity of views, as well as the differences among the authors may be due to the lack of common parameters for evaluation and diagnosis, and lack of deeper knowledge about the consequences of frenulum alterations.

There are just a few protocols to evaluate this mucous median tunic fold, which restricts movements or functions performed by the tongue, and most of the published protocols do not show a detailed description of how to perform the evaluation. This is because the authors, in general, already have a predetermined concept of what a lingual frenulum alteration is. Consequently, few explanations provide adequate information for identifying an altered lingual frenulum.

Some of the existing protocols evaluate the size of the frenulum, where it is attached, and propose objective measurements (Marchesan, 2005; Ruffoli, Giambelluca, Scavuzzo, 2005). Other authors focus on one or another specific item which they considered a determining factor to diagnose frenulum alterations (Jorgenson, Shapiro, Salinas, Levin, 1982; Williams & Waldron, 1985; Lee, Kim, Lim, 1989; Notestine, 1990; Fleiss, Burger, Ramkumar, Carrington, 1990; Marmet, C., Shell, Marmet, R., 1990; Kotlow, 1999; Messner & Lalakea, 2000;

Messer et al, 2000b; Hogan et al, 2005). There are two protocols designed to evaluate babies (Hazelbaker, 1993, Martinelli, Marchesan, Rodrigues, Berretin-Felix, 2012).

Diagnosing frenulum alterations can be difficult because the evaluator has to be aware of the anatomy of the tongue, including different aspects of the frenulum and adjacent regions. In addition, the evaluator must know what functions may be affected by the alterations of the lingual frenulum.

Considering the diversity of the points of view mentioned, this author has designed a protocol with scores to evaluate the tongue and the frenulum. As the tongue takes part in orofacial functions, aspects such as shape, size, and range of movements must be tested.

## **METHODS**

From a previous lingual frenulum evaluation used by Marchesan (2005). A new protocol with history and clinical examination was designed. The history relates the subject's complaints and general identification questions. The specific questions investigate the relationship among the frenulum and other aspects, such as family history, breastfeeding, swallowing, chewing, oral habits, speech, voice and previous frenulum surgeries. The clinical examination was divided in two parts: the first investigates general aspects of the frenulum and tongue, and the second investigates the tongue's mobility and position in the oral cavity, speech production and compensatory patterns used by the subject.

Ten speech language pathologists experienced in orofacial myology used the protocol with different groups of subjects. 1235 subjects were evaluated during 3 years. From the experience of these ten speech language pathologists, the protocol was re-structured, and scores were added. The absence of alteration (normal tongue and frenulum) was scored zero. The alterations observed were scored in ascending order. Four additional speech language pathologists experienced in orofacial myology were trained by the researcher to administer the final version of the protocol. The protocol was given to 239 subjects in 2008 and 2009: 160 children between 7 years and 2 months old and 11 years and 7 months old; and to 79 adults from 16 years and 8 months or older. Subjects with craniofacial abnormalities or with intellectual or motor limitations were not evaluated.

All participants were informed on the objectives of the study and signed a "Term of Free and Clarified Consent". The Committee of Ethics in Research of CEFAC - Health and Education, process No. 032-08, approved the project.

## **RESULTS**

**A new lingual frenulum protocol with scores was designed.** According to the scores, the frenulum can be considered altered or normal. When the sum of general tests is equal or higher than 3, frenulum may be altered. The interference of the lingual frenulum in oral functions can be considered when the sum of functional tests is equal or higher than 25.

Appendix A shows the lingual frenulum protocol with history and clinical examination. Appendix B shows photographs of normal frenulum as well as different types of frenulum alterations that can be diagnosed during evaluation. Appendix C shows a table with the pictures used to evaluate speech, and a table for taking notes about the patient's speech production.

## **DISCUSSION**

This study describes a lingual frenulum protocol with a specific history and a clinical examination with scores. The clinical examination has four general tests and four functional tests. The purpose of the protocol is to diagnose possible frenulum alterations, as well as to provide information to relate anatomical frenulum alterations to functional alterations.

The need for a specific frenulum protocol was due to divergences and doubts on how to evaluate, classify and name the alterations in the lingual frenulum (Messner & Lalakea, 2000; Messer et al, 2000; Singh & Kent, 2000; Zemlin, 2000; Galvão, 2001; Moore & Dalley, 2001; Ballard et al, 2002; Hogan et al, 2002; Navarro & Lópes, 2002; Lalakea & Messner, 2003; Stedman, 2003; Dorland, 2004; Marchesan, 2004; Gonçalves & Ferreiro, 2006; Hall &

## **CONTACT AUTHOR**

**Irene Queiroz Marchesan, PhD**  
Speech Language Pathologist  
Specialist in Orofacial Myology

Renfrew, 2006; Ostapiuk, 2006; Segal et al, 2007; Brito, Marchesan, Bosco, Carrilho, Rehder, 2008; Geddes et al, 2008; Karabulet, 2008; Marchesan, Rehder, Martinelli, Costa, Araújo, Caltabellotta, Oliveira, 2009; Suter & Bornstein, 2009; Forlenza et al, 2010; Merdad & Mascarenhas, 2010; Miranda & Milroy, 2010; Post et al, 2010). Furthermore, the protocol should also establish possible relationships among the oral functions and the frenulum alteration, since that seemed to be a controversial point in scientific literature (Navarro & Lopez, 2002; Marchesan, 2004; Gonçalves & Ferreiro, 2006; Segal et al, 2007; Karabulut et al, 2008; Marchesan et al, 2009; Suter & Bornstein, 2009).

Since a lingual frenulum protocol evaluating simultaneously features of the tongue, frenulum and the oral functions with scores was not found in the literature (Jorgenson et al, 1982; Williams & Waldron, 1985; Lee et al, 1989; Fleiss et al, 1990; Marmet, et al, 1990; Notestine, 1990; Halzebaker, 1993; Kotlow, 1999; Messner & Lalakea, 2000; Messner et al, 2000; Ballard et al, 2002; Hogan et al, 2005; Marchesan, 2005; Ruffoli et al, 2005; Brito et al, 2008), this new protocol was designed. A consistent protocol with scores consistently applied by many evaluators specifically trained in its use, may reduce the number of controversies about possible lingual frenulum alterations (Marchesan, 2004; Suter & Bornstein, 2009).

The present protocol has been applied and tested consistently for many years. It has proven to be an efficient tool to evaluate lingual frenulum alterations.

## **CONCLUSION**

This paper proposed a lingual frenulum protocol with scores, which enables health professionals, such as: speech language pathologists, dentists and physicians to evaluate and diagnose lingual frenulum alterations. This lingual frenulum protocol with scores has been an efficient tool to diagnose altered lingual frenulum.

**CEFAC'S Director**  
**Phone number: 55-11-3868.0818**  
[Irene@cefac.br](mailto:Irene@cefac.br) [www.cefac.br](http://www.cefac.br)

## REFERENCES

- Ballard, J., Auer, C., Khoury, J.** (2002). Ankyloglossia: assessment, incidence, and effect of frenuloplasty on the breastfeeding dyad. *Journal of Pediatrics*. 110(5):1-6.
- Brito, S.F., Marchesan, I.Q., Bosco, C.M., Carrilho, A.C.A., Rehder, M.I.** (2008). Frênulo lingual: classificação e conduta segundo ótica fonoaudiológica, odontológica e otorrinolaringológica. *Revista CEFAC*. 10(3):343-51.
- Dorland, S.** (2004) *Illustrated Medical Dictionary*. 26th ed. Saunders Company.
- Fleiss, P., Burger, M., Ramkumar, H., Carrington, P.** (1990). Ankyloglossia: a cause of breastfeeding problems? *Journal of Human Lactation*. 6(3):128-9.
- Forlenza, G.P., Black, N.M.P., McNamara, E.G., Sullivan, S.E.** (2010). Ankyloglossia, Exclusive Breastfeeding, and Failure to Thrive. *Journal of Pediatrics*. 125:1500-4.
- Galvão, Filho. S.** (2001) *Dicionário Odonto-Médico Inglês-Português*. São Paulo: Santos.
- Geddes, D.T., Langton, D.B., Gollow, I., Jacobs, L.A., Hartmann, P.E., Simmer, K.** (2008). Frenulotomy for Breastfeeding Infants With Ankyloglossia: Effect on Milk Removal and Sucking Mechanism as Imaged by Ultrasound. *Journal of Pediatrics*. 122:e188e-94.
- Gonçalves, C.S., Ferreiro, M.C.** (2006). Estudo da relação entre presença de frênulo lingual curto e/ou anteriorizado e a dorsalização do fone [r] na articulação da fala. *Revista CEFAC*. 8(1):56-60.
- Hall, D.M.B., Renfrew, M.J.** (2005). Tongue-tie: common problem or old wives' tale. *Archives of Disease in Childhood*. 90:1211-1215. doi: 10.1136/adc.2005.077065
- Hazelbaker, A.K.** (1993) *The assessment tool for lingual frenulum function (ATLFF): Use in a lactation consultant private practice*. Pasadena, CA: Pacific Oaks College. Thesis.
- Hogan, M., Westcott, C., Griffiths, M.** (2005). Randomized, controlled trial of division of tongue-tie in infants with feeding problems. *Journal of Paediatrics and Child Health*. 41(5-6):246-50.
- Jorgenson, R., Shapiro, S., Salinas, C., Levin, L.** (1982). Intraoral findings and anomalies in neonates. *Journal of Pediatrics*. 69(5):577-82.
- Karabulut, R., Sonmez, K., Turkyilmaz, Z., Demirogullari, B., Ozen, I.O., Bagbanci, B., et al.** (2008). Ankyloglossia and effects on breast-feeding, speech problems and mechanical/social issues in children. *Belgian Ear Nose Throat Journal (B-ENT)*. 4(2):81-5.
- Kenneth N.A. (ed.)** *Mosby's. Medical, nursing, e allied health dictionary* 5ª ed. St Louis, Missouri; Mosby, Inc; 1998.
- Knox, I.** (2010). Tongue-tie and Frenotomy in the Breastfeeding Newborn. *Journal of the American Academy of Pediatrics (NeoReviews)*. 11(9):513-9.
- Kotlow, L.A.** (1999). Ankyloglossia (tongue-tie): A diagnostic and treatment quandary. *Quintessence International*. 30:259-62.

- Lalakea, M.L., Messner, A.H.** (2003). Ankiloglossia: the adolescent and adult perspective. *Otolaryngology Head Neck Surgery*, 128:746-52.
- Lee, S.K., Kim, Y.S., Lim, C.Y.** (1989). A pathological consideration of ankyloglossia and lingual myoplasty. *Taehan Chikkwa Uisa Hyophoe Chi*. 27(3):287-308.
- Marchesan, I.Q.** (2004). Lingual frenulum: classification and speech interference. *International Journal of Orofacial Myology*. 30:31-8.
- Marchesan, I.Q.** (2005). Lingual frenulum: quantitative evaluation proposal. *International Journal of Orofacial Myology*. 31:39-48.
- Marchesan, I.Q.; Rehder, MIBC; Martinelli, RLC; Costa, MLVCM; Araújo, RLT; Caltabellotta, MRT; Oliveira, LR.** (2009). Fala e frênulo da língua. Existe alguma relação? In: XVII Congresso Brasileiro de Fonoaudiologia, 2009, Salvador. *Revista da Sociedade Brasileira de Fonoaudiologia*. Suplemento Especial. São Paulo: Sociedade Brasileira de Fonoaudiologia.
- Marmet, C., Shell, E., Marmet, R.** (1990). Neonatal frenotomy may be necessary to correct breastfeeding problems. *Journal of Human Lactation*. 6(3):117-21.
- Martinelli RLC, Marchesan IQ, Rodrigues AC, Berretin-Felix G.** Protocolo de avaliação do frênulo da língua em bebês. *Revista CEFAC*. 2012;14(1):138-145.
- Merdad, H., Mascarenhas, A.K.** (2010). Ankyloglossia may cause breastfeeding, tongue mobility, and speech difficulties, with inconclusive results on treatment choices. *Journal of Evidence-Based Dental Practice*. 10(3):152-3.
- Messner, A., Lalakea, M., Macmahon, J., Bair, E.** (2000). Ankyloglossia: incidence and associated feeding difficulties. *Archives Otolaryngology Head & Neck Surgery*. 126(1):36-9.
- Messner, A., Lalakea, M.** (2000). Ankyloglossia: controversies in management. *International Journal of Pediatric Otorhinolaryngology*. 54(2):123-31.
- Miranda, B.H., Milroy, C.J.** (2010). A quick snip - A study of the impact of outpatient tongue-tie release on neonatal growth and breastfeeding. *Journal of Plastic, Reconstructive & Aesthetic Surgery*. 63(9):e683-5.
- Moore, K.L., Dalley, A.F.** *Anatomia orientada para a clínica*. 4ª ed. Rio de Janeiro: Guanabara Koogan; 2001.
- Navarro, N.P., López, M.** (2002). Anquiloglossia en niños de 5 a 11 años de edad. Diagnóstico y tratamiento. *Revista Cubana Estomatología*. 39(3):3-7.
- Notestine, G.** (1990). The importance of the identification of ankyloglossia (short lingual frenulum) as a cause of breastfeeding problems. *Journal of Human Lactation*. 6(3):113-5.
- Ostapiuk, B.** (2006). Tongue mobility in ankyloglossia with regard to articulation. *Annales Academiae Medicae Stetinensis*. 52 Supplement 3:37-47.
- Post, E.D., Rupert, A.W., Schulpen, T.W.** (2010). Problematic breastfeeding due to a short frenulum. *Nederlands Tijdschrift voor Geneeskunde*. 154:A918.
- Ruffoli, R., Giambelluca, M.A., Scavuzzo, M.C., et al.** (2005). "Ankyloglossia: a morphofunctional investigation in children". *International Journal of Oral Diseases*. 11(3): 170-4.

**Segal, L.M., Stephenson, R., Dawes, M., Feldman, P.** (2007). Prevalence, diagnosis, and treatment of ankyloglossia: methodological review. *Canadian Family Physician*. 53(6):1027-33.

**Singh, S., Kent, R.D.** *Dictionary of speech-language pathology*. San Diego, California: Singular's; 2000.

**Stedman, T.L.** *Medical Dictionary. 27th ed.* Rio de Janeiro: Guanabara Koogan; 2003.

**Suter, V.G., Bornstein, M.M.** (2009). Ankyloglossia: facts and myths in diagnosis and treatment. *Journal of Periodontology*. 80(8):1204-19.

**Tuli, A., Singh, A.** (2010). Monopolar diathermy used for correction of ankyloglossia. *Journal of Indian Society of Pedodontics and Preventive Dentistry*. 28:130-3.

**Wallace, H., Clarke, S.** (2006). Tongue-tie division in infants with breast-feeding difficulties. *International Journal of Pediatric Otorhinolaryngology*. 70(7):1257-61.

**Williams, W.N., Waldron, C.M.** (1985). Assessment of lingual function when ankyloglossia (tongue-tie) is suspected. *The Journal of the American Dental Association*. 110(3):353-6.

**Zemlin, W.R.** *Princípios de Anatomia e Fisiologia em Fonoaudiologia 4ª ed.* Porto Alegre: Artmed; 2000.

## Appendix A LINGUAL FRENULUM PROTOCOL

### HISTORY

<b>Name:</b> _____		<b>Gender</b>
F ( ) M ( )		
<b>Examination date:</b> ___ / ___ / ___	<b>Age:</b> ___ years and ___ months	<b>Birth:</b> ___ / ___ / ___
<b>Responsible:</b> _____		<b>Relative:</b> _____

<b>Studying:</b> <input type="checkbox"/> yes <input type="checkbox"/> no	<b>Grade:</b> _____
<b>Working:</b> <input type="checkbox"/> yes <input type="checkbox"/> no	<b>Profession:</b> _____
<b>Worked before</b> <input type="checkbox"/> no	<input type="checkbox"/> yes <b>Professional Area:</b> _____
<b>Practicing sports:</b> <input type="checkbox"/> no	<input type="checkbox"/> yes <b>Type:</b> _____

<b>Address:</b> _____		
<b>City:</b> _____	<b>State:</b> _____	<b>ZIP:</b> _____
<b>Phone:</b> Home: (____) _____	Office: (____) _____	Cell: (____) _____
<b>e-mail:</b> _____		
<b>Father's name:</b> _____		<b>Mother's name:</b> _____
<b>Siblings:</b>		
<input type="checkbox"/> no	<input type="checkbox"/> yes	How many: _____

Who referred patient for evaluation ( <i>Name, specialist, phone</i> ): _____
<b>Why?</b> _____

**Main** \_\_\_\_\_ **complaint:** \_\_\_\_\_

**Other complaints affecting:**

(0) no (1) sometimes (2) yes

( ) lips	( ) tongue	( ) sucking	( ) chewing	( ) deglutition
( ) breathing	( ) speech	( ) lingual frenulum	( ) voice	( ) hearing
( ) learning	( ) facial aesthetic	( ) posture	( ) occlusion	( ) headache
( ) TMJ clicking	( ) TMJ pain	( ) neck pain	( ) shoulders pain	
( ) mouth opening difficulty	( ) mandible range of motion		( ) Other	

**Family history – any other relative has frenulum alteration**

<input type="checkbox"/> no <input type="checkbox"/> yes	Who? _____	Surgery was necessary: <input type="checkbox"/> yes <input type="checkbox"/> no
--	------------	---

**Health problems**

<input type="checkbox"/> no <input type="checkbox"/> yes	What kind: _____
--	------------------

**Breathing problems**

<input type="checkbox"/> no <input type="checkbox"/> yes	What kind: _____
--	------------------





## LINGUAL FRENULUM PROTOCOL (Continued)

### CLINICAL EXAMINATION

#### I – GENERAL TESTS

**Measurements using a caliper. Larger or equal 50,1% (0) – Less or equal 50% (1) FINAL RESULT =**

Take measurements from superior right or left incisive to the inferior right or left incisive. Consider the same tooth for all the measurements.	Value in millimeters
Open mouth wide	
Open mouth wide with the tongue tip touching the incise papilla	
Difference between the two measurements, in percentage	%

**Alterations during tongue elevation (best result = 0 worst result = 2) FINAL RESULT =**

<i>Open mouth wide; raise the tongue without touching the palate</i>	NO	YES
1. Tip of the tongue's shape: oblong or square	(0)	(1)
2. Tip of the tongue's shape: like a heart	(0)	(1)

**Frenulum fixation. Add A and B (best result = 0 e worst result = 3) Final result =**

<b>A – Mouth floor:</b>	
Visible only from the sublingual caruncles	(0)
Visible from inferior alveolar crest	(1)

**Fixation in another point:**

---

<b>B – Sublingual:</b>	
In the middle of the tongue	(0)
Between the middle and the apex of the tongue	(1)
At the apex	(2)

**Clinical frenulum classification (best result = 0 e worst result = 2) Final result =**

Normal (0)	Borderline (1)	Altered (2)
------------	----------------	-------------

**If the frenulum was considered altered it would be because:**

The frenulum seems normal but it is attached between the middle and the apex of the tongue	The frenulum is short	The frenulum is short and it is fixed between the middle and the apex of the tongue
Ankyloglossia (frenulum attached to apex of the tongue)	Another reason	Unsure

**General tests evaluation total score: best result = 0 worst result = 8**

**When the score of the general tests evaluation is equal or greater than 3, the frenulum may be considered altered.**

**II – FUNCTIONAL TESTS**

**Tongue mobility (best result = 0 worst result = 14). Final result =**

	Successful	Partially successful	Unsuccessful
Protrude and retract	(0)	(1)	(2)
Touch the superior lip with the apex	(0)	(1)	(2)
Touch the right commissura labiorum	(0)	(1)	(2)
Touch the left commissura labiorum	(0)	(1)	(2)
Touch U&L molars	(0)	(1)	(2)
Apex vibration	(0)	(1)	(2)
Sucking against the palate	(0)	(1)	(2)

**Tongue position during rest (best result = 0 e worst result = 4). Final result =**

Not visible	(0)
On the floor of the mouth	(1)
Protrudes between the teeth	(2)
Laterally protrudes between teeth	(2)

**Speech (best result = 0 e worst result =12) Final result =**

**Test 1 – Informal speech**

e.g.: What is your name? How old are you? Do you study/work? Tell me about your school/work. Tell me about something interesting.

**Test 2 – Ask to count from 1 to 20. Ask to say the days of the week. Ask to say the months of the year.**

**Test 3 – Ask to name the pictures from the picture table**

Speech tests	Omission		Substitution		Distortion	
	No	Yes	No	Yes	No	Yes
1	(0)	(1)	(0)	(1)	(0)	(2)
2	(0)	(1)	(0)	(1)	(0)	(2)
3	(0)	(1)	(0)	(1)	(0)	(2)

**Check for which sound there is omission or substitution or distortion**

p	t	k	b	d	g	m							
n	□	f	s	x	v	z							
j	l	□	r	rr	{S}	{R}							
pr	br	tr	dr	cr	gr	fr	vr	pl	bl	cl	gl	fl	vl

**If the alteration occurs in only one or two tests, identify in which test there was alteration**

**Other aspects to be observed during speech (best result = 0 e worst result =10) Final result =**

<b>Mouth opening:</b>	(0) adequate	(1) reduced	(1) open wide
<b>Tongue position:</b>	(0) adequate	(1) on the floor	(2) protruded (2) visible sides
<b>Mandible movements:</b>	(0) no alteration	(1) right displacement	(1) left displacement (1) forth displacement
<b>Speed:</b>	(0) adequate	(1) increased	(1) reduced
<b>Speech precision:</b>	(0) adequate	(1) altered	
<b>Voice:</b>	(0) no alteration	(1) altered	

**Functional evaluation total score: best result = 0 and worst result = 40**

**When the score of the functional evaluation is equal or greater than 25, the frenulum can be considered altered.**

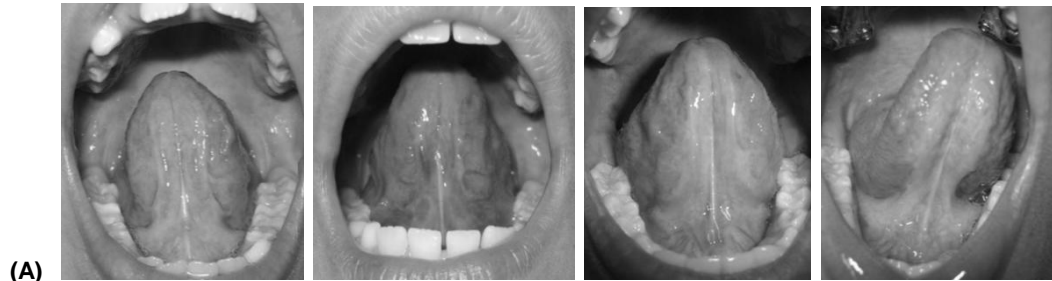**Documentation:**

**Photography and video of tongue mobility and speech evaluation**

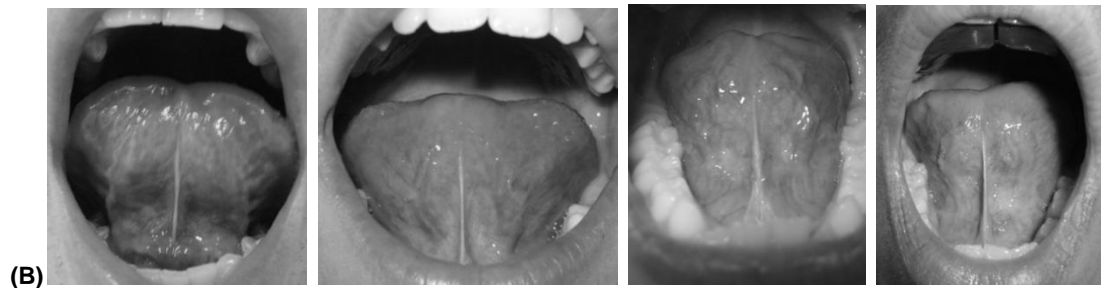
**APPENDIX B:  
LINGUAL FRENULUM PROTOCOL (Instructional Photos)**

**Examples of different frenulum types**

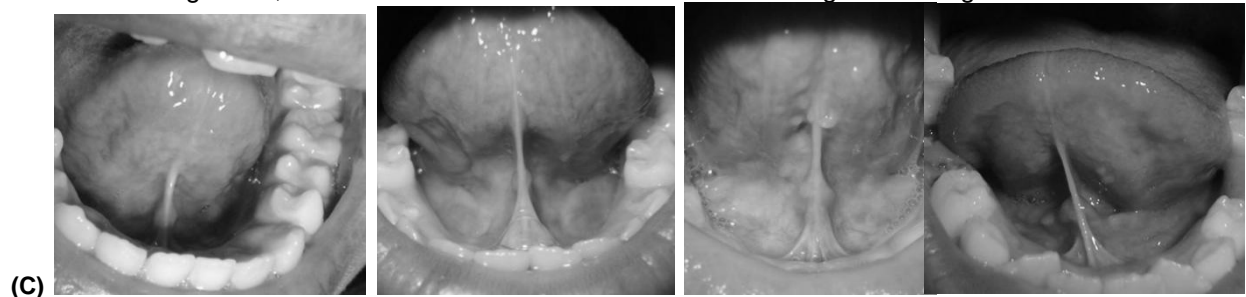
- (A) Normal: the lingual frenulum is attached from underneath the tongue to the floor of the mouth. In general, the frenulum is visible from the tongue down to the saliva caruncles.



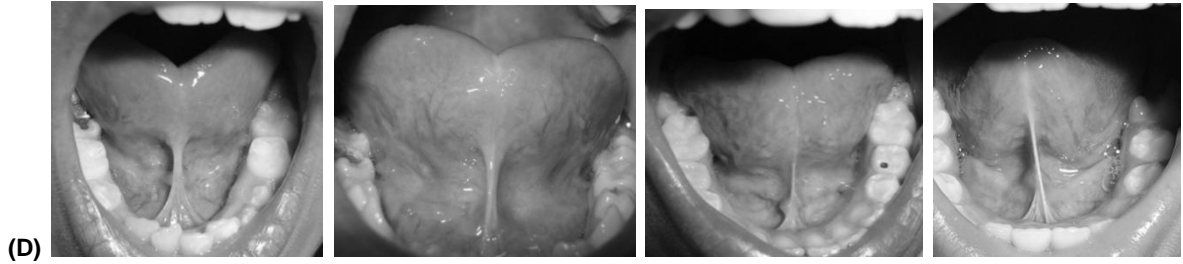
- (B) Anterior: when the frenulum is attached, underneath the tongue, at any point between the tongue midpoint and the apex.



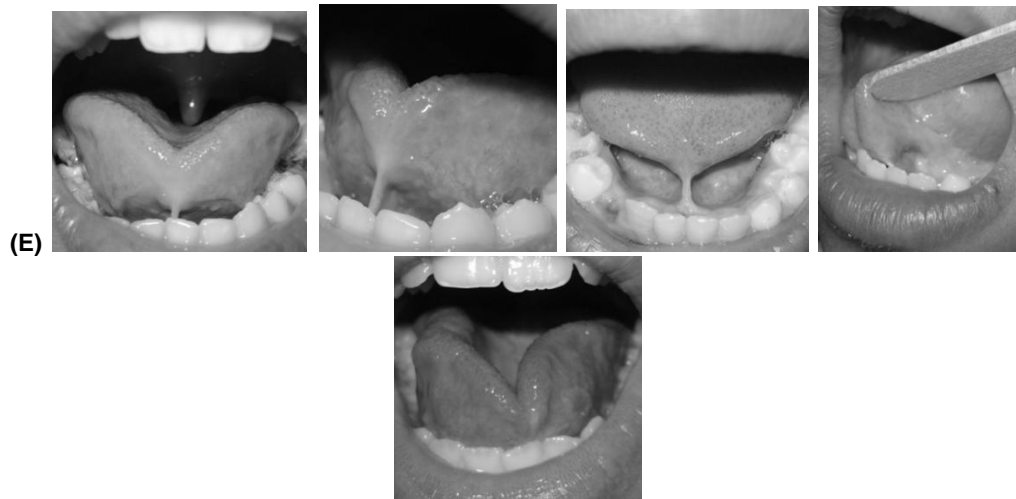- (C) Short: it is attached underneath the tongue, as in the normal frenulum, but it is shorter than normal. In general, the frenulum is still visible underneath the tongue touching the alveolar crest.



D) Short and anterior: a combination of (B) and (C).



(E) Ankyloglossia: when there is lack of or minimal lingual frenulum or the frenulum is attached to the apex of the tongue so that the tongue movements are very much limited.



**APPENDIX: C  
LINGUAL FRENULUM PROTOCOL**

**TABLE WITH THE WORDS FOR SPEECH EVALUATION**

<b>Picture</b>	<b>Patient production</b>	<b>Picture</b>	<b>Patient production</b>
Clock		Cockroach	
Pencil		Strawberry	
Cat		Giraffe	
Dice		Door	
Bird		Rabbit	
Sofa		Lion	
Scissors		Plate	
House		Train	
Bike		Dragon	
Star		Letter	
Truck		License plate	
Eye		Arrow	
Key		Blouse	
Airplane		Flute	
Butterfly		Radio	
Dog		Car	
Phone		Zebra	
Flower		Blue wing	
Gift		Umbrella	
Alligator		Fish	
Hammer		Horse	
Cross		Ladybug	
Grass		Chicken	
Owl		Crown	
Athlete		Globe	

## PICTURE TABLE FOR THE SPEECH EVALUATION

